

Clinical Practice Guidelines for Achondroplasia*

Takuo Kubota^{1,6}, Masanori Adachi^{2,6}, Taichi Kitaoka^{1,6}, Kosei Hasegawa^{3,6}, Yasuhisa Ohata^{1,6}, Makoto Fujiwara^{1,6}, Toshimi Michigami^{4,6}, Hiroshi Mochizuki^{5,6}, and Keiichi Ozono^{1,6}

¹Department of Pediatrics, Osaka University Graduate School of Medicine, Osaka, Japan

²Department of Endocrinology and Metabolism, Kanagawa Children's Medical Center, Yokohama, Japan

³Department of Pediatrics, Okayama University Graduate School of Medicine, Dentistry and Pharmaceutical Sciences, Okayama, Japan

⁴Department of Bone and Mineral Research, Research Institute, Osaka Women's and Children's Hospital, Osaka Prefectural Hospital Organization, Osaka, Japan

⁵Division of Endocrinology and Metabolism, Saitama Children's Medical Center, Saitama, Japan

⁶Guidelines Development Committee for Achondroplasia

Abstract. Achondroplasia (ACH) is a skeletal dysplasia that presents with limb shortening, short stature, and characteristic facial configuration. ACH is caused by mutations of the *FGFR3* gene, leading to constantly activated FGFR3 and activation of its downstream intracellular signaling pathway. This results in the suppression of chondrocyte differentiation and proliferation, which in turn impairs endochondral ossification and causes short-limb short stature. ACH also causes characteristic clinical symptoms, including foramen magnum narrowing, ventricular enlargement, sleep apnea, upper airway stenosis, otitis media, a narrow thorax, spinal canal stenosis, spinal kyphosis, and deformities of the lower extremities. Although outside Japan, papers on health supervision are available, they are based on reports and questionnaire survey results. Considering the scarcity of high levels of evidence and clinical guidelines for patients with ACH, clinical practical guidelines have been developed to assist both healthcare professionals and patients in making appropriate decisions in specific clinical situations. Eleven clinical questions were established and a systematic literature search was conducted using PubMed/MEDLINE. Evidence-based recommendations were developed, and the guidelines describe the recommendations related to the clinical management of ACH. We anticipate that these clinical practice guidelines for ACH will be useful for healthcare professionals and patients alike.

Key words: achondroplasia, systematic review, guideline

*The Japanese version of these guidelines were published on the website of the JSPE (<http://jspe.umin.jp/medical/files/guide20190111.pdf>) on January 11, 2019.

Received: July 31, 2019 Accepted: August 7, 2019

Corresponding author: Takuo Kubota, MD, PhD., Department of Pediatrics, Osaka University Graduate School of Medicine, 2-2 Yamadaoka, Suita, Osaka 565-0871, Japan

E-mail: tkubota@ped.med.osaka-u.ac.jp



This is an open-access article distributed under the terms of the Creative Commons Attribution Non-Commercial No Derivatives (by-nc-nd) License <<http://creativecommons.org/licenses/by-nc-nd/4.0/>>.

Copyright© 2020 by The Japanese Society for Pediatric Endocrinology



List of Recommendations

CQ1: Is a cranial MRI recommended to identify spinal cord compression due to foramen magnum stenosis?

A cranial MRI is recommended to identify spinal cord compression due to foramen magnum stenosis. (Recommendation grade 1, evidence level B)

CQ2: Is foramen magnum decompression effective for spinal cord compression due to foramen magnum stenosis?

Foramen magnum decompression is recommended for managing spinal cord compression due to foramen magnum stenosis associated with neurological symptoms, abnormal neurological findings, and central respiratory disorders. (Recommendation grade 1, evidence level B)

CQ3: Is cranial MRI useful for identifying hydrocephalus?

An MRI cranial examination is recommended to identify ventricular enlargement with neurological symptoms (hydrocephalus). (Recommendation grade 1, evidence level B)

CQ4: Is shunt surgery effective for managing ventricular enlargement?

Shunt surgery is recommended for managing ventricular enlargement associated with neurological symptoms (hydrocephalus). (Recommendation grade 1, evidence level C)

CQ5: What diagnostic methods are recommended for sleep apnea?

Simple sleep studies and polysomnography are selected based on the circumstances. (Recommendation grade 1, evidence level C)

CQ6: Is noninvasive positive pressure ventilation useful for managing obstructive sleep apnea?

Noninvasive positive pressure ventilation is suggested for managing obstructive sleep apnea. (Recommendation grade 2, evidence level B)

CQ7: Is tonsillectomy or adenoidectomy useful for managing obstructive sleep apnea?

We suggest surgical treatment when obstructive sleep apnea is present with tonsillar/adenoid hypertrophy. (Recommendation grade 2, evidence level B)

CQ8: Does onset of pulmonary hypertension occur during achondroplasia?

(Recommendation grade none, evidence level D)

CQ9: Is spinal decompression useful for managing spinal canal stenosis?

Spinal decompression is recommended for managing spinal canal stenosis associated with neurological symptoms. (Recommendation grade 1, evidence level B)

CQ10: What is the frequency of developmental disorders?

Delayed speech is observed in 25% of cases. (Recommendation grade 1, evidence level C)

CQ11: At what age is limb lengthening appropriate?

We suggest that leg lengthening should be possible after the age of 12 years, under informed assent. (Recommendation grade 2, evidence level D)

Introduction

Summary and diagnosis of achondroplasia

Achondroplasia (MIM 100800, hereafter referred to as "ACH") is a skeletal dysplasia that presents with limb shortening and short stature (1, 2). Although the exact frequency of achondroplasia is unknown, it is estimated to affect more than 250,000 individuals worldwide and is reported to occur with an incidence of one in every 10,000 to 30,000 births (2, 3).

It is characterized by a conspicuous rhizomelic short-limb short stature, characteristic facial configuration (relatively large cranium, protruding forehead, a

flattened nasal bridge, hypoplasia of the midface, and relative protrusion of the mandible), and a trident configuration of the hands. Plain X-ray images show shortened tubular bones with increased diameter, broad and irregular metaphyses of the long bones that exhibit cupping, shortened femoral necks, fibula bones that are longer than tibia bones, narrowing of the distance between the lumbar pedicles, posterior scalloping of the lumbar vertebral bodies, narrowing of the sciatic notch, a horizontal acetabular roof, shortening of the base of the skull, and facial hypoplasia (Fig. 1). Platyspondyly is sometimes observed in the neonatal period. The diagnosis is made when the symptoms and bone X-ray images are consistent (Table 1) (<http://www.nanbyou.com>).

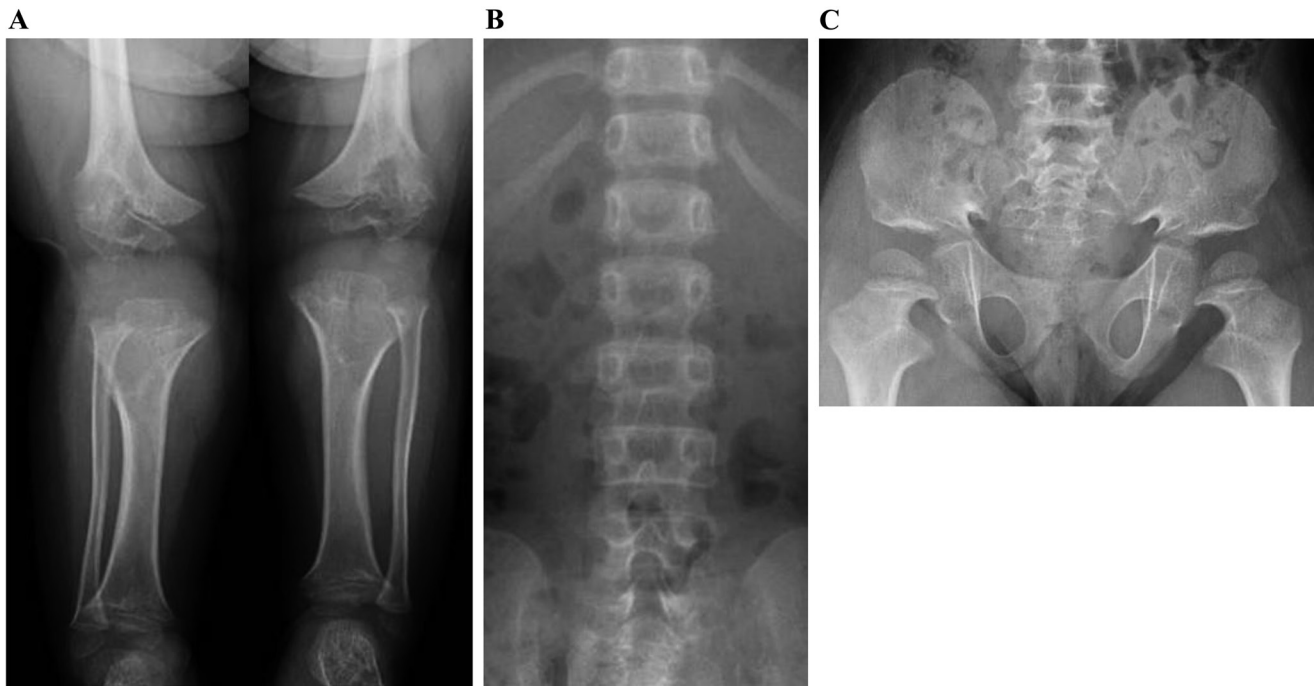


Fig. 1. X-ray images in a patient with achondroplasia. (A) Thick and short tibia; the width of the femur and tibia metaphysis is wide, irregular and is cupped; fibula that is longer than the tibia. (B) Narrowing in the interpedicular distance in the lumbar spine. (C) Sciatic notch narrowing, flattening of acetabular roof, rectangular or rounded iliac wing, shortened femoral neck

or.jp/entry/4571). An enlarged head circumference (above the 97th percentile), shortening of the femoral bone (below the 5th percentile), and trident hand are observed in the fetal period (4). The characteristic clinical symptoms and radiological findings for ACH are observed starting from the neonatal period, although approximately 20% of patients are not diagnosed at this time (5). Foramen magnum narrowing, ventricular enlargement, sleep apnea, upper airway stenosis, otitis media, a narrow thorax, spinal canal stenosis, spinal kyphosis, malformation of the lower extremities, and joint hyperextensibility are also observed with ACH. Further information is available from the numerous reports available on the Gene Review Japan homepage (<http://grj.umin.jp/grj/achondroplasia.htm>). Outside Japan, papers on health supervision aid the follow-up of patients with achondroplasia (4–6). However, the details are based on reports and questionnaire survey results, due to a lack of data with a high level of evidence.

Etiology

A Gly380Arg mutation of the *FGFR3* gene, located on chromosome 4p26.3, is observed in $\geq 97\%$ of patients with ACH (nearly always c.1138G>A, but sometimes c.1138G>C), and the genotype homogeneity is high (7, 8) (GeneReviewsJapan: <http://grj.umin.jp/grj/achondroplasia.htm>). The disease is characterized by an autosomal dominant inheritance, although approximately 80% of cases are due to new spontaneous mutations in patients born to healthy parents (2).

Pathophysiology

FGFR3 binds to FGF18 or FGF9 and as it undergoes autophosphorylation, it activates downstream intracellular signaling molecules. Along this route, it passes from FRS2 α to GRB, SOS, and RAS and activates the transcription factor Sox9 via the Raf/MEK/ERK pathway. One route suppresses the hypertrophy of chondrocytes, while the other results in activation of Stat1, which in turn activates p21 and suppresses chondrocyte proliferation.

When FGFR3 possesses a mutation as a result of ACH, it is constantly activated, autophosphorylates FGF receptors, and causes the activation of downstream intracellular signaling molecules Raf/MEK/ERK and Stat1 (8). This results in the suppression of chondrocyte differentiation, and cartilage matrix production and proliferation. This in turn impairs endochondral ossification, the process by which bones are formed from cartilage, resulting in poor extension of the long bones, such that patients present with short-limb dwarfism.

The majority of the bones that make up the vertebral bodies and the base of the skull are formed by means of endochondral ossification; thus, the ossification of the aforementioned bones is impaired, resulting in foramen magnum stenosis, ventricular enlargement, and hydrocephalus due to poor circulation of cerebrospinal fluid, and spinal canal stenosis.

Table 1. Diagnostic criteria for achondroplasia

| |
|---|
| A. Symptoms |
| <ol style="list-style-type: none"> 1. Short stature with marked shortening of the extremities due to rhizomelia (Short stature of -3 SD below average, shortening of extremities with an arm span/body height of < 0.96) 2. A characteristic facial configuration (relatively large cranium, protruding forehead, a flattened nasal bridge, central facial hypoplasia, and relative protrusion of the mandible): head circumference > 1 SD above average 3. Trident hand (widening of the space between the middle and ring fingers when the fingers are splayed) |
| B. Findings on plain X-ray examination |
| <ol style="list-style-type: none"> 1. Limbs (frontal view): Tubular bones are thick and short; metaphysis of long bones having a large width, irregular with a cup-shaped deformity (cupping); shortening of the femoral neck; belt-like translucency of proximal part of femur; characteristic reverse V shape on the distal femur epiphysis; fibula is longer than the tibia (fibula length/tibia length) > 1.1; determination is difficult during infancy because ossification is not yet progressed. 2. Spinal column (frontal view, lateral view): Progressive decrease in the interpedicular distance in the lumbar spine (interpedicular distance ratio of L4/L1 < 1.0) (not prominent during infancy); concavity to the posterior lumbar vertebral body. 3. Pelvis (frontal view): Narrowing of the sciatic notch; iliac wing hypoplasia with a rectangular or round shape; the acetabular roof is flat, and the cavity of the lesser pelvis resembles a champagne glass. 4. Cranium (frontal view, lateral view): Basicranial shortening, facial bone hypoplasia 5. Hand (frontal view): Trident hand, and tubular bones are thick and short. |
| C. Differential diagnosis |
| The following disorders are included in the differential diagnosis: Skeletal dysplasia, such as hypochondroplasia, metatropic dysplasia, and pseudoachondroplasia. When the differential diagnosis is difficult based on clinical symptoms and X-ray findings, a genetic diagnosis should be performed. |
| D. Genetic testing |
| G380R mutation is observed on the fibroblast growth factor receptor 3 (<i>FGFR3</i>) gene. |
| <Diagnostic category> |
| Definite: Satisfies all 3 items from A and 5 items from B, and excludes differential diagnosis diseases identified in C. Or, satisfies D for Probable or Possible. |
| Probable: Satisfies at least 2 items from A and at least 3 items from B, and excludes differential diagnosis diseases identified in C. |
| Possible: Satisfies at least 2 items from A and at least 2 items from B, and excludes differential diagnosis diseases identified in C. |

Designated intractable disease 276: <http://www.nanbyou.or.jp/entry/4571>.

Symptoms and complications

1. Height

Although shortening of the extremities is observed from the neonatal period, the neonatal body length is not affected to the same extent. The mean body length is 47.5 cm for boys and 47.0 cm for girls, and the short stature becomes more conspicuous as the child grows (9). No growth spurt is observed during puberty, and the degree of dwarfism appears comparatively worse at this time. The adult height is approximately 130 cm for men and 124 cm for women (9). The height of adults with achondroplasia in reports from the USA is similar to that in reports from Japan (10).

2. Monitoring, development, and quality of life

Monitoring and early intervention are important because it has been reported that sudden death caused by spinal cord compression due to foramen magnum stenosis in the head and neck transition region is observed in 5%–10% of these cases (5, 11). It is essential to monitor the growth and development and to evaluate them by referring to the standards

for ACH in terms of the patient's height, body weight, head circumference, and development (2, 5, 10, 12). The head circumference in achondroplasia is usually larger than in unaffected children, and gross motor skills are often delayed, although fine motor skills are usually not delayed. The process of speech development varies, and overall, most patients with ACH have no cognitive development problems. Patients with ACH will have physical disabilities; they may face limitations in locomotion, self-care, daily activities, or school activities (2, 11). It should be recognized that children with ACH will have a different development profile compared to healthy children (12, 13). It has been reported that adult patients with ACH generally have a lower annual income, academic background, self-esteem, and quality of life (QOL) compared to their healthy siblings (14). Researching and, as much as possible, eliminating the causes of disability in daily activities or social activities are essential for patients with ACH (15).

3. Foramen magnum stenosis

Spinal cord compression at the cervicomedullary junction due to foramen magnum stenosis is common, but

the frequency of symptomatic spinal cord compression is low (11). However, symptoms such as sleep apnea, respiratory disorders, myelopathy, hydrocephalus, and sudden death have been observed. Moreover, it has been reported that a foramen magnum decompression procedure was needed on 6.7%–13.3% of patients with ACH by the age of 2 (16, 17). There is no consensus on how best to evaluate the complications related to foramen magnum stenosis, or the optimal time for intervention. To decrease spinal cord compression at the cervicomedullary junction, the head and neck region should be treated with care during the early stages of infancy and sitting position walkers or baby sling carriers should not be used during this period. Recently, a multidisciplinary expert panel announced consensus guidelines regarding foramen magnum stenosis based on the Delphi method (18). An imaging examination is recommended in cases where abnormalities are observed in the medical history, physical findings, and polysomnography.

4. Ventricular enlargement

Ventricular enlargement is commonly observed in achondroplasia. Furthermore, basicranial hypoplasia due to impaired endochondral ossification produces jugular vein stenosis, which in turn blocks the cerebrospinal fluid flow. Elevated dural venous sinus pressure is also said to contribute to ventricular enlargement (18). The ventricular enlargement in ACH is generally communicating, and true hydrocephalus (ventricular enlargement accompanied by neurological symptoms) is rare; however, this is one of the more severe complications (2). Symptoms of hydrocephalus include irritability, anterior fontanelle bulging, headache, vomiting, papilledema, abducens nerve paralysis, hemiplegia, loss of consciousness, hypertension, and bradycardia. Careful observation is recommended, especially up to around the age of 1 yr (11). A ventriculoperitoneal (VP) shunting procedure should be conducted on hydrocephalus in which intracranial hypertension symptoms are observed.

5. Spinal canal stenosis

Spinal canal stenosis is frequently observed in older children and adults with ACH (1). The symptoms of spinal canal stenosis include pain in the extremities, numbness, muscle weakness, motor impairment, intermittent claudication, bladder, and rectal disorders. It has been reported that a diagnosis of spinal canal stenosis is made for 6.5% of patients by age 20 and 17% of patients by age 40, and approximately 40% of these patients undergo surgery (19). Lumbar spinal canal stenosis is caused by narrow vertebral columns, protruding intervertebral discs, protrusion of the vertebral bodies, vertebral body kyphosis and wedge deformation, excessive lumbar lordosis, and instability of the vertebral bodies (11). Challenging sitting positions should be avoided to reduce spinal canal deformity. It is desirable that spinal laminectomy be performed by an experienced surgeon before irreversible damage to

the spine occurs (1).

6. Spinal kyphosis

Thoracolumbar vertebral kyphosis is a frequently observed complication of ACH. Reversible kyphosis is observed in at least 90% of infants with ACH, but the condition improves when the infants start to walk (11). However, the kyphosis progresses during childhood and adolescence, and irreversible kyphotic deformity is observed in 15%–30% of adults; we believe that the kyphosis contributes to the spinal canal stenosis. It is considered that being in a seated posture early on is a risk factor for cuneiform deformation of the anterior vertebral bodies, kyphosis, and spinal canal stenosis (20, 21). It is recommended that the patients not be forced into a seated posture until the patient can maintain a sitting posture independently.

7. Obstructive sleep apnea and respiratory symptoms

Respiratory signs and symptoms are frequently observed in patients with ACH. Thoracic cage hypoplasia, upper airway obstruction, and compression in the cervicomedullary transition region are considered to be the main causes (11). Upper airway obstruction is common, and 10%–85% of patients require treatment for sleep apnea or chronic respiratory disorders. The frequency of upper airway obstruction is high, and polysomnography is reported to be effective (22). Many cases have been reported of patients with ACH who have central/obstructive sleep apnea syndrome, gastroesophageal reflux, restrictive lung disease, and chronic heart failure (23). Regular evaluation of sleep apnea through polysomnography is recommended so that the timing for surgical intervention is not missed (5).

8. Otitis media, hearing loss, and dentistry

Persistent or recurrent otitis media is frequently observed in children with ACH. It is reported that almost 90% of children with ACH have experienced otitis media by age 2, and chronic and recurrent otitis media is observed in at least 25% of the children (19). The relationship with central facial hypoplasia, shortened eustachian tube, small pharynx, relative hypertrophy of the adenoids/tonsils has also been pointed out. The consensus for recurrent otitis media is proactively to perform adenoid tonsillectomy or a ventilation tube placement procedure (1). It is reported that at least 50% of children with ACH will undergo the ventilation tube placement procedure by age 5 (6). Recurrent otitis media is a risk factor for conductive hearing loss, and at least 50% of adult patients with ACH will experience hearing difficulties (24, 25). Hearing loss causes speech delays and can also affect communication skills, so early hearing tests are recommended. In addition, irregular dentition sometimes becomes a problem (2), and central facial hypoplasia is assumed to be a primary factor.

9. Complications in the limbs

Rhizomelic short-limbed dwarfism is a symptom of

ACH, and as a result, the patient may be unable to reach his/her parietal region, central back area, or buttocks (11). In addition, impaired extension of the elbow and hip joints and hyperextension of the finger joints are frequently observed. Disorders of hip joint extension are presumed to contribute to lumbosacral lordosis and lumbar back pain. Furthermore, genu varum is often observed in adolescents and adults with ACH, and genu varum malformations exhibit rapid progression from infancy to school age; this is observed in $\geq 40\%$ of adults and can cause chronic lower limb pain and gait abnormalities (19). It has been reported that 22% of patients underwent tibial osteotomy primarily between the ages of 12 and 20 yr.

10. Obesity

Obesity is a common complication of ACH, and affects obstructive sleep apnea, genu varum, spinal canal stenosis, and lordosis (11). Cardiovascular deaths are commonly reported in patients with ACH, and it is important to manage the body weight appropriately with reference to a growth curve specific to ACH (26–30).

Treatment

1. GH treatment

GH treatment is approved for patients with ACH satisfying the following criteria in Japan. To start treatment for ACH with human GH, the patient must satisfy all of the following selection criteria (i)–(v): (i) At least age 3 yr for both boys and girls (body height measurement while standing can be used); (ii) bone age for boys is under 17 yr, and for girls is under 15 yr; (iii) the current body height is 3 SD below standard compared to children of the same sex and age; (iv) the patient must exhibit the physical characteristics of ACH; (v) an MRI • CT examination shows no complications such as foramen magnum stenosis, lumbar spinal canal stenosis, hydrocephalus, and spinal/cauda equina compression sufficient to warrant surgical treatment. In addition, no clinically challenging neurological symptoms due to this compression should be detectable. There are some reports of the short-term efficacy of GH treatment on body height, including those in which the improvement in body height SDS was 1.3 SD with a low dose, and 1.6 SD with a high dose within 5 yr (31). Furthermore, it has been demonstrated that the rate of height gain was 2.6 cm/yr in Year 1, and 0.7 cm/yr in Year 2 (32). On the other hand, there are also reports that the SDS improvement stopped at 0.3 SD after 3 yr of GH treatment (33). In examinations of adult height, increases of 0.6 SD (3.5 cm) in males and 0.5 SD (2.8 cm) in females (34) have been reported.

2. Limb lengthening procedures

Limb lengthening procedures are usually performed to improve the short stature and shortened extremities in patients with ACH. Lower limb lengthening procedures utilizing external fixators require a long treatment

period and there are frequent complications; therefore, it is desirable that the decision to undergo leg lengthening procedures should be made by the patient themselves. By considering at what age the patient would be able to do this, this procedure is only recommended for patients older than 12 yr (35). In a meta-analysis of lower limb lengthening procedures for ACH and hypochondroplasia, the average age was 14.5 yr, the average body height gained was 9.5 cm, the healing index (number of days required to lengthen the bone by 1 cm) was 30.8 d/cm, and the complication rate for lower leg or thigh lengthening procedures was 0.68 (36). Reported sequelae include drop foot, residual peroneal nerve paralysis, and valgus deformities of the knee and ankle joints. In a report of lower limb extension procedures in Korea, the average age was 14 yr and 4 mo, the average gained body height for the thigh bone was 8.4 cm, and 9.8 cm for the tibia. The healing index for the femur was 28.1 d/cm and 10.7 d/cm for the tibia. The rates of complications for bone lengthening procedures were 0.41 for the femur, and 0.41 for the tibia (37). According to previous reports, complications include bone fractures after external fixator removal and hip joint contractures. There are few reports that summarize the upper limb lengthening procedures in achondroplasia. The average gained extension is 8.3–9.8 cm, the healing index is 24.8–31.1 d/cm, and the complication for upper arm bone extension procedures is 0.79–0.88 (38, 39). The reported sequelae include a restricted range of joint motion and fractures. It is important to conduct sufficient discussions before surgery between the patients, their families, and the orthopedic surgeon.

Methods

Organization and funding source for ACH clinical practice guidelines

These guidelines were prepared by the Guidelines Development Committee with a research fund subsidy for the “Construction of Medical Treatment Network for Skeletal Dysplasias Aiming at the Establishment of Clinical Practice Guidelines” (Principal Investigator: Keiichi Ozono) of Practical Research Project for Rare/Intractable Diseases Project of Japan Agency for Medical Research and Development (National Research and Development Agency).

The affiliation and specialty of the Guidelines Development Committee members and conflict of interest (COI) disclosure are shown in **Appendix Table 1**.

Process of the guideline preparation

In preparing these guidelines, clinical questions (CQs) were established in order to study the complications of achondroplasia with reference to “Guidance for the Creation of Clinical Practice Guidelines 2014”; based on the full body of evidence obtained from a systematic review (SR), the recommendation statements,

recommendation strengths, and commentary were created for each CQ. In addition, a summary of achondroplasia was mentioned in the text above. The final grading of the strength of the recommendations was determined during discussions involving all members of the guideline development committee.

1. Creating the clinical questions (CQs)

The PICO model (P: patients, problem, population, I: interventions, C: comparisons, controls, comparators, O: outcomes) was used for components of the CQ. With regards to creating the CQs for patient outcomes and the assessment of the relative importance of the extracted outcomes, a method was used wherein points from 1 to 9 were assigned for each outcome, with a higher score representing a more important the outcome for the patient. Points were classified as follows: 1 to 3 points were “not important”, 4 to 6 points were “important”, and 7–9 points were “critical”; the outcomes in the SR that were actually performed were carried out for what was judged to be “critical” with an importance higher than 6 points.

2. Literature search

For each CQ, the preparation committee members decided on search keywords, and after creating a search query, a search was performed using PubMed/MEDLINE (search date: January 14, 2017). The primary screening of the results was conducted by the preparation committee members and the SR committee members; items that were judged not relevant to the CQ based on the titles and abstracts were excluded. In the secondary screening, the SR committee members read the full texts and selected the papers that met the selection criteria. Furthermore, subsequent papers that were judged to be useful were added later (final addition date: March 1, 2018).

3. Level of evidence in the literature and overall evaluation of evidence

Because ACH is a rare disease, there were no randomized comparative trials; case-controlled studies, cross-sectional studies, and case reports were the main focus. In these guidelines, the strength of the evidence was defined as shown in **Table 2**, and the strength of the recommendation was ultimately determined

by evaluating the balance between benefits and risks (**Table 3**).

The strength of the recommendations for CQ was determined with the approval of all guidelines development committee members after weighing the benefits against the risks, after four SR committee members each discussed the recommended phrases prepared by the members.

4. External evaluation

- ① Opinions of the Japanese Society for Pediatric Endocrinology members (August 16, 2018 to September 30, 2018)
- ② Evaluations and Proposals of the Japanese Society for Pediatric Endocrinology Guideline Committee (September 25, 2018)
- ③ Reviewed by the Japanese Society for Pediatric Endocrinology Board of Directors (December 7, 2018 to December 21, 2018)
- ④ Approved by the Japanese Society for Pediatric Endocrinology Board of Directors (December 21, 2018)

5. Opinions from patient organizations

Comments were solicited from two patient groups (Tsukushinokai and Tsukushinbo) (August 25, 2018)

Precautions for use

These guidelines have been developed to assist healthcare professionals and patients in making appropriate decisions in specific clinical situations. In practical evaluations, healthcare staff members should make a comprehensive decision based on the condition of the individual patient. These guidelines are designed to aid in clinical practice and are not necessarily intended to limit individual medical care.

Time of revision

These clinical practice guidelines are expected to be revised within 5 yr. The preparation committee members for the revision will be recruited based on instructions from the Japanese Society for Pediatric Endocrinology. Furthermore, if a new situation emerges

Table 2. Strength and definition of evidence

| | |
|------------------|---|
| A (strong) | Strongly confident about the estimate of the effect |
| B (intermediate) | Moderately confident about the estimate of the effect |
| C (weak) | Limitedly confident about the estimate of the effect |
| D (very weak) | Little confidence about the estimate of the effect |

Table 3. Strength of recommendation

| | |
|-------------------------|--|
| 1 Strong Recommendation | Recommended “to be implemented” or “not to be implemented” |
| 2 Weak Recommendation | Proposed “to be implemented” or “not to be implemented” |
| None | Neither can be recommended or proposed |

that is considered to have a significant impact on the details of these guidelines, and if the Board of Directors of the Japanese Society for Pediatric Endocrinology decides that emergency measures are required, these may be revised as “proposals.”

Clinical Manifestations and Diagnosis of ACH

CQ1: Is a cranial MRI recommended to identify spinal cord compression due to foramen magnum stenosis?

[Recommendation]

Cranial MRI is recommended to identify spinal cord compression due to foramen magnum stenosis. (Recommendation grade 1, evidence level B)

[Interpretation]

Endochondral ossification is impaired in achondroplasia (ACH). Narrowing of the foramen magnum is observed in ACH because the occipital bone that forms the foramen magnum grows through endochondral ossification. Narrowing of the foramen magnum sometimes causes spinal cord compression at the cervicomedullary junction, which can cause central sleep apnea (CSA) or sudden death (18). In addition, neck pain, symptoms of bulbar paralysis, bladder dysfunction, paralysis, increased tendon reflexes, and clonus are observed.

Out of 51 patients with ACH, examinations were conducted on 17 patients who underwent MRI testing and polysomnography (PSG) within 6-month intervals (average age: 2.4 yr) (40). Spinal cord compression at the head and neck transition region was observed in 8 patients (concavity/deformity of the spine at the narrowing portion), syringomyelia was observed in 1 patient, and high signal intensity on the spine with T2 high-contrast image was observed in 3 patients. Clonus and low muscle tone were observed in 1 patient with syringomyelia. CSA was observed in 1 patient with high signal intensity in a T2 high-contrast image. Sleep apnea (SA) and dysphagia were observed in 1 patient with spinal cord compression. Also, the MRI observations (degree of narrowing by measurement, T2 high signal intensity, and compression observation) did not correlate with the seriousness of SA.

Out of 10 patients with ACH in whom neurological abnormalities were observed (average age: 13 mo), a high signal intensity was observed in the T2 high-contrast image of the spine at the head and neck transition region in all 9 cases in which MRI was conducted (41).

In total, 26 patients with ACH who were introduced to orthopedics for limb lengthening, and in whom neurological symptoms and abnormalities were observed (average age: 11 yr), underwent MRI (42). Narrowing was observed in 23 patients, of which, serious cervical cord compression (kinking or pinching on the cervix and medulla oblongata junction of the foramen magnum) was

observed in 13 patients, and syringomyelia in 1 patient.

The age at which neurological respiratory symptoms develop can vary, and it is difficult to determine a recommended age for MRI testing (43). There are cases in which the patient has had neurological respiratory symptoms since the neonatal period (43), and careful observation is required. If neurological respiratory symptoms are present, then an MRI scan should be performed. If there are no symptoms, the Health Supervision of the American Academy of Pediatrics in the year 2005 recommends screening with MRI, or CT and PSG (5). On the other hand, the consensus by an international expert panel in 2015 recommends an overnight sleep study, but not MRI or CT, for the screening of asymptomatic cases (18).

From the above, cranial MRI examination is useful for the identification of spinal cord compression due to foramen magnum stenosis, as screening with MRI of asymptomatic patients remains controversial. Great caution should be exercised to find neurological symptoms and abnormalities.

CQ2: Is foramen magnum decompression effective for spinal cord compression due to foramen magnum stenosis?

[Recommendation]

Foramen magnum decompression is recommended for managing spinal cord compression due to foramen magnum stenosis associated with neurological symptoms and abnormal neurological findings, and central respiratory disorders. (Recommendation grade 1, evidence level B)

[Interpretation]

Endochondral ossification is impaired in ACH. Narrowing of the foramen magnum is observed in ACH because the occipital bone that forms the foramen magnum grows through endochondral ossification. Stenosis of the foramen magnum sometimes causes spinal cord compression at the cervicomedullary junction, which can cause central sleep apnea (CSA) or sudden death (18). The foramen magnum decompression procedure is conducted in approximately 5%–25% of cases (17). The surgeries conducted are often suboccipital craniectomy and C1 laminectomy (17, 44, 45). Investigations should be conducted to determine whether or not foramen magnum decompression is effective for managing spinal cord compression due to foramen magnum stenosis associated with neurological symptoms and abnormal neurological findings, and central respiratory disorder.

In a case-control study of 167 patients with ACH, the 109 patients who were followed-up were divided into two groups, with and without the foramen magnum decompression procedure, to compare the patients' health-related QOL (46). The foramen magnum decompression procedure was conducted on 55 patients who satisfied 2 out of the following 3 criteria (average age: approximately 18 yr): (i) Lower

limb tendon reflex, clonus, (ii) CSA/central hypopnea, (iii) an MRI examination showing compression or reduction of cerebrospinal fluid. The postoperative observation period was 10.2 yr, and the 54 patients who did not meet these criteria or had no neurological symptoms (average age: approximately 31 yr) did not undergo the foramen magnum decompression procedure. According to the SF-36 instrument, which evaluates health-related QOL, there were no significant differences between the two groups in terms of age and sex, even after adjustment. Deaths occurred in 1 patient from the group that received the decompression procedure, and 12 patients from the group that did not have the decompression procedure. It was concluded that the foramen magnum decompression procedure was effective since there were no differences according to the SF-36 between the group with the decompression procedure conducted (more serious) and the group without the decompression procedure (milder).

There were 43 patients with ACH (mean age: 70 mo) who underwent foramen magnum decompression (45). The following symptoms were observed in 42 patients (tendon reflex acceleration or clonus: 21 patients; hypotonia: 12 patients; obstructive sleep apnea: 15 patients; CSA: 7 patients). The mean observation period was 70 mo, and improvement of symptoms was observed in all patients. The complications observed were leakage of cerebrospinal fluid (7 patients); reoperation (5 patients); infection (2 patients); and pseudomeningocele (1 patient).

There were 37 patients with ACH with neurological symptoms who underwent foramen magnum decompression (mean age: 29 mo) (44). The symptoms observed were 28 patients with hypotonia; 12 patients with myelosis; and 5 patients with growth retardation. An improvement in symptoms was observed in 29 out of 37 patients. The mean observation period was 67.4 mo. The complications observed were dural laceration (3 patients) and bleeding from heterotopic venous sinus (1 patient).

Virtually all of the 18 patients with ACH with neurological and respiratory symptoms (mean age: 23 mo) underwent foramen magnum decompression (17). At least one of the symptoms from the group including quadriplegia, tendon reflex acceleration, clonus, sleep apnea (SA), and cyanosis was observed in all 15 patients before the procedure. Respiratory arrest was observed in 1 patient, 1 patient had hydrocephalus, and 1 patient had a T2 high signal intensity in a high-contrast image in the MRI examination of the top of the cervical cord. The mean observation period was 8 yr and 2 mo. Complications related to the surgery included 2 patients with dura mater injury, and 1 patient with bleeding from the dural venous sinus. In total, 14 out of 18 patients had a favorable long-term clinical course. One case with respiratory arrest did not improve, and the patient died. 1 patient had a tracheotomy procedure, continued CSA, and had an unknown long-term prognosis.

In total, 10 patients with ACH who had abnormal neurological findings underwent foramen magnum

decompression (mean age at surgery: 12.5 mo [4–23 mo]) (41). The mean postoperative observation period was 21.7 mo. Improved motor function was observed in 7 patients, there were no changes in 2 patients, and exacerbation in 1 patient. An improvement in SA was observed in 7 patients, but it worsened in 1 patient.

Among the 53 patients with ACH who were referred with no CSA or neurological symptoms (average age: 11 mo), and the 52 patients with ACH who were referred due to concerns over respiratory symptoms and neurological symptoms (average age: 24 mo), the foramen magnum decompression procedure was performed on those in whom neurologic abnormalities were observed, 5 patients and 5 patients (16), respectively. Neurological symptoms improved in 9 out of 10 patients, while postoperative neurological symptoms persisted in 1 patient for whom surgery was delayed. Postoperative transient cerebrospinal fluid leakage was observed in 1 patient.

From the above, symptoms can improve in many cases when foramen magnum decompression is conducted in patients with ACH with foramen magnum stenosis accompanied by neurological symptoms, neurological abnormalities, or central respiratory disorder. Because treatment has poor efficacy when the intervention is too late, neurological symptoms and findings, and respiratory status are assessed in patients with ACH so as not to overlook patients with surgery indications. Furthermore, according to an international expert panel, in cases of spinal cord compression due to foramen magnum stenosis or spinal signal changes, or depressions in the spinal cord (indentations) due to neurological abnormalities and substantial foramen magnum stenosis from an MRI examination, a foramen magnum decompression procedure is recommended with semi-urgency (18). On the other hand, in cases with only spinal cord compression due to the foramen magnum stenosis without spinal cord signal changes or neurological symptoms, foramen magnum decompression is not recommended.

CQ3: Is cranial MRI useful for identifying hydrocephalus?

[Recommendation]

MRI cranial examination is recommended to identify ventricular enlargement with neurological symptoms (hydrocephalus). (Recommendation grade 1, evidence level B)

[Interpretation]

Ventricular enlargement is commonly observed in ACH. Basicranial hypoplasia due to impaired endochondral ossification produces jugular vein stenosis, which in turn blocks the cerebrospinal fluid flow. Elevated dural venous sinus pressure due to jugular vein stenosis causes impaired cerebrospinal fluid resorption, which in turn causes ventricular enlargement. In addition, the development of venous collaterals is thought to contribute

to the stability of the pathological conditions (47). Most of the hydrocephalus in ACH is “communicating,” so there are few symptoms other than that of head enlargement and ventricle enlargement, which is also expressed as compensated hydrocephalus (18). However, hydrocephalus is considered to be a serious complication of ACH because some patients show neurological symptoms and require treatment (2). Symptoms of hydrocephalus include irritability, a bulging anterior fontanelle, enlarged head circumference, headache, vomiting, papilledema, abducens nerve paralysis, hemiplegia, loss of consciousness, hypertension, and bradycardia. An urgent head CT examination is often performed in the course of hydrocephalus examination; however, a cranial MRI examination is not only used for an assessment of ventricular enlargement, but there is an advantage in that it is easy to evaluate foramen magnum stenosis.

In total, 17 asymptomatic patients with ACH (mean age: 4.8 yr) underwent cranial MRI scans (48). Progressive ventricular dilation was recognized in 5 patients (1 to 8 yr old), non-progressive ventricular enlargement in 6 patients (7 mo to 12 yr of age), and normal-sized ventricles in 6 patients (6 mo to 15 yr of age).

A cranial MRI examination was performed for 10 patients with ACH suspected of spinal cord compression in the head and neck transition area (mean age: 2.9 yr) (49). The cerebral ventricular size can range from moderately enlarged to normal. Progressive ventricular enlargement was observed in 2 out of 6 patients who could be continuously evaluated. In addition, 6 patients had foramen magnum stenosis, and 2 patients with cerebellar tonsillar herniation had central apnea and intermittent suboccipital headaches.

Cranial MRI examination was performed on 8 patients with ACH (mean age: 5.7 yr) with no abnormal neurological signs (50). Ventricular enlargement was seen in 5 patients, among those, 1 was severe, 2 were moderate, and 2 were mild.

Cranial MRI examination and neuropsychological evaluation were performed on 16 ACH school-aged patients (mean age: 7.4 yr) (51). Of the 11 patients who underwent MRI examination, 9 patients showed ventricular enlargement, while 2 did not.

Cranial MRI examination was performed in 2 patients with ACH with chronic headache (12 and 14 yr old) (52). Enlargement was noted in the lateral ventricle and the third ventricle, and an improvement of symptoms was observed by endoscopic third ventriculostomy (endoscopic third ventriculostomy).

A cranial MRI examination was performed in 2 patients with ACH who had neurological symptoms and ventricular enlargement (53). One of these was a girl with ventricular enlargement who was 7 yr of age; MRI examination showed ventricular enlargement and foramen magnum stenosis, and ventricular pressure monitoring showed brain hypertension. The other patient was a boy with visual impairment who was 17 mo old;

an MRI examination showed ventricular enlargement and foramen magnum stenosis, ophthalmic examination revealed optic nerve atrophy, and ventricular pressure monitoring showed brain hypertension. The brain pressure was decreased by a ventriculoperitoneal (VP) shunt in both of these patients.

From the above, cranial MRI examination is useful for the identification of ventricular enlargement and hydrocephalus. However, since the therapeutic intervention is not determined solely by MRI findings, continuous evaluation is necessary together with assessing the presence of progressive enlargement of the head circumference and clinical symptoms.

CQ4: Is shunt surgery effective for managing ventricular enlargement?

[Recommendation]

Shunt surgery is recommended for managing ventricular enlargement associated with neurological symptoms (hydrocephalus). (Recommendation grade 1, evidence level C)

[Interpretation]

Ventricular enlargement is commonly observed in ACH. Basicranial hypoplasia due to impaired endochondral ossification produces jugular vein stenosis, which in turn blocks the cerebrospinal fluid flow. Elevated dural venous sinus pressure is also assumed to contribute to ventricular enlargement (18). The ventricular enlargement in ACH is generally communicating, and although true hydrocephalus (ventricular enlargement with neurological symptoms) is rare, it is a serious complication (2). Symptoms of hydrocephalus include irritability, a bulging anterior fontanelle, enlarged head circumference, headache, vomiting, papilledema, abducens nerve paralysis, hemiplegia, loss of consciousness, hypertension, and bradycardia. In cases of hydrocephalus that lack symptoms other than head enlargement and ventriculomegaly, a ventriculoperitoneal (VP) shunt is generally not employed. The proportion of cases undergoing shunt surgery ranges from 4.3%–50%, with reports varying widely (17). Also, to prevent slit ventricle syndrome after shunting when there is significant intracranial hypertension, the use of a flow-regulated valve (automatic variable resistance valve) system or a programmable valve (variable pressure type valve) system is advisable.

In 2 patients with ACH (4 yr and 2 mo old and 4 yr and 8 mo old) who showed vomiting or horizontal nystagmus and ventricular enlargement, symptoms disappeared after the VP shunt procedure was performed; the observation periods were 4 yr and 2 yr, respectively.

When a VP shunt procedure was performed on an ACH patient (15 yr old) with hemifacial spasm, headache, and ventricular enlargement, the symptoms disappeared (54, 55).

When endoscopic third ventriculostomy was

performed on two patients with ACH (12 and 14 yr old) who had chronic headache and enlarged lateral and third ventricles, the symptoms improved (52).

In cases with hydrocephalus and headache, it has been reported that the symptoms have disappeared following endoscopic third ventriculostomy (17).

Although only a small number of case reports have been seen, it has been recognized that the neurological symptoms have disappeared, and the VP shunt is considered to be effective for ventriculomegaly with neurological symptoms. Experience demonstrates the efficacy of endoscopic third ventriculostomy (ETV) (18). However, an adequate preliminary investigation is required in order to determine whether the neurological symptoms are caused by ventricular enlargement. In addition, for hydrocephalus cases with foramen magnum stenosis, while some are of the opinion that foramen magnum decompression improves ventricular enlargement (18), exacerbation has also been reported (47), and therefore no consensus has been reached.

CQ5: What diagnostic methods are recommended for sleep apnea?

[Recommendation]

Simple sleep studies and polysomnography are selected based on the individual circumstances. (Recommendation grade 1, evidence level C)

[Interpretation]

It has been reported that breathing disorders during sleeping, including sleep apnea (SA), are observed in 30%–60% of infants with ACH (18). SA is considered to be a cause of increased infant mortality in patients with ACH and is classified into obstructive, central, and mixed types. It has been reported that central sleep apnea (CSA) has frequently been found in cases where a decompression procedure is required for spinal cord compression at the cervical spinal cord junction due to foramen magnum stenosis (16). Although polysomnography (PSG) is recommended as an assessment of SA, the available facilities for children are limited (18). In PSG, oxygen saturation (SpO₂), nose and mouth airflow, snoring, body position, respiratory movement on chest and abdomen, electrocardiogram, EEG, eye movement chart, the mentalis muscle EMG chart, and the anterior tibialis muscle EMG chart are evaluated. On the other hand, in the simple sleep test, an SpO₂ monitor and nasal pressure sensor are used. Simple sleep studies cannot differentiate between the central and obstructive types of apnea. Also, in Japan, facilities for which PSG can be performed for children are limited, so a comprehensive evaluation should be made using screening tests such as interviews, medical examinations, home videography, and overnight pulse oximetry. However, it should be noted that although PSG is the gold standard for sleep testing, a sleep test intermediate between simple sleep test and PSG can be performed (56).

PSG was performed on 88 patients with ACH, including 5 patients who had undergone tracheostomy and 7 patients who were receiving oxygen (median age: 1.2 yr) (57). The median number of episodes of obstructive sleep apnea (OSA) is 0 times/hour (range: 0 to 19.2), and for CSA accompanied by oxygen reduction it is 0.5 times/examination (0 to 49). The minimum SpO₂ is 91% (50%–99%). Approximately 48% of the ACH children had abnormal breathing during sleep (mostly hypoxia), and it was concluded that a relatively high number of patients suffer from severe sleep apnea.

PSG was performed in 22 patients with ACH (mean age: approximately 3 yr) (58). Symptoms including malaise (4), excessive sweating (15), SA (7), labored breathing (6), and cyanosis (1) were observed. A decreased oxygen concentration in 19 patients, CSA in 1 patient, and OSA in 8 patients were also observed.

In studies where PSG was performed in 46 patients with ACH (mean age: 3.9 yr), asymptomatic cases were also included, and snoring was observed in 32 patients (59). Some patients were also affected by oral respiration, nocturnal awakening, and daytime somnolence. OSA was observed in 25 patients; the median OSA index was 0.8 events/h (range: 0 to 28.5), the central apnea index was 0.8 events/h (0 to 6.2), and the apnea-hypopnea index (AHI) was 6.5 events/h (0 to 33.5). There were 21 patients with an AHI < 5, 13 patients with mild OSA (AHI: 5 to 10), 7 patients with moderate OSA (AHI: 10 to 15), and 5 patients with severe OSA (AHI > 15). The mean of the lowest values of all 46 patients' SpO₂ was 88.0% (72 to 96).

In 43 patients with ACH (mean age: 3.9 yr), sleep tests (41 patients) and PSG (2 patients) were conducted (60). Among 43 patients, adenoid and tonsil removal (6), adenoid removal (9), and brain surgery (6: of these, 5 had foramen magnum decompression) were performed before the sleep examination. OSA was observed in 24 patients, which could be broken down as 13 mild (AHI 1.5–5), 4 moderate (AHI 5–10), and 7 severe cases (AHI 10 or more). The minimum SpO₂ (%) for mild OSA patients was 87% ± 7% (mean ± SD), for moderate patients with OSA was 86% ± 6%, and for severe patients with OSA was 75% ± 14%.

Clinical information, sleep function test, and lung function tests were performed in 17 patients with ACH (median age: 11 mo) who had respiratory symptoms before the age of 1 yr (23). Signs and symptoms include OSA, neurological symptoms, and right ventricular hypertrophy. OSA was observed during sleep studies in all patients. The number of decreases to 4% of the SpO₂ was 0 to 82 times/examination, the proportion below 92% of SpO₂ during sleep was 0% to 95%, and the number of CSA events was 0 to 5 times/examination. As a result of subsequent scrutiny, adenectomy and tonsillectomy were performed in 7 patients, and foramen magnum decompression was performed in 2 patients.

From the above, PSG is useful for evaluating the SA of ACH. Although only a few studies have been conducted, a simple sleep test can also be useful as a

screening for SA. When SA is found, it is important to search for causes such as hypertrophy of the adenoids and tonsils, and foramen magnum stenosis.

CQ6: Is noninvasive positive pressure ventilation useful for managing obstructive sleep apnea?

[Recommendation]

Noninvasive positive pressure ventilation is suggested for managing obstructive sleep apnea. (Recommendation grade 2, evidence level C)

[Interpretation]

Obstructive sleep apnea (OSA) is common in patients with ACH, and this complication is reported in more than 50% of patients (18). A narrow trachea, midfacial hypoplasia, and muscle hypotonia are believed to be the primary factors. The main noninvasive positive pressure ventilation (NPPV) methods used are continuous positive airway pressure (CPAP) and bilevel positive airway pressure (BiPAP) (61).

An overnight sleep test and somatosensory evoked potential test were performed in 30 ACH patients (median age: 6.6 yr), and treatment was deemed necessary in 17 patients (62). Nasal CPAP was used in 13 patients, adenoid tonsillectomy was performed in 3 patients, and weight loss therapy was performed with 1 patient. The results showed improvement in the respiratory disorder indices, nocturnal body motion and waking, and obstructive events.

Polysomnography (PSG) was performed in 45 patients with ACH (mean age: 3.9 yr), of whom, 25 were diagnosed with obstructive sleep apnea (59). Among these, nasal CPAP was used in 9 patients, and improvements in respiratory index, awakening index, and SpO₂ were observed.

A sleep test was implemented in 43 patients with ACH (mean age: 3.9 yr), (simple sleep test in 41 patients and PSG in 2 patients) (60). Procedures had been performed before the sleep test in some of these 43 patients, including adenoid and tonsil removal (6 patients), adenoid removal (9 patients), and brain surgery (6 patients; of these, 5 underwent foramen magnum decompression). OSA was observed in 24 patients. There were no severe OSA cases among the patients who underwent adenoid tonsillectomy (apnea-hypopnea index (AHI) \geq 10). In total, 2 patients who received CPAP therapy showed improved SpO₂ at night. Although OSA was not observed, 1 patient in whom alveolar hypoventilation was recognized showed improvement when CPAP was received.

Among 30 patients with ACH (median age: 3.0 yr), NPPV was performed for 5 patients in whom alveolar hypoventilation persisted (63). Three patients continued to exhibit abnormal overnight PSG findings following upper airway surgery. CPAP was received by 1 infant, and ventilation by BiPAP was used in the remaining 4 patients; the results showed a reduced AHI and

improved SpO₂. Furthermore, improvements in speech development, concentration ability, and daily fatigue were observed.

From the above, although there are few cases in which the effects of NIPPV were examined in patients with ACH, this is suggested as one of the treatments for OSA since its efficacy has been reported as described above.

CQ7: Is tonsillectomy or adenoidectomy useful for managing obstructive sleep apnea?

[Recommendation]

We suggest surgical treatment when obstructive sleep apnea is present with tonsillar/adenoid hypertrophy. (Recommendation grade 2, evidence level C)

[Interpretation]

Obstructive sleep apnea (OSA) is common in patients with ACH and has been reported in \geq 50% of patients with ACH (18). Midfacial hypoplasia and relative hypertrophy of the adenoids and tonsils are considered to be the main contributing factors (5). It has been reported that while some cases have responded well to adenotonsillectomy, in some cases there was no improvement in apnea following surgery (4).

Sleep tests were performed among 43 patients with ACH (mean age: 3.9 yr) (simple sleep test in 41 patients and polysomnography (PSG) in 2 patients) (60). The procedures were performed before the sleep test in some of these 43 patients, including adenoid and tonsil removal (6 patients), adenoid removal (9 patients), and brain surgery (6 patients; of these, 5 underwent foramen magnum decompression). OSA was observed in 24 patients, but there were no severe OSA cases (apnea-hypopnea index [AHI] \geq 10) in patients who underwent adenotonsillectomy.

Adenotonsillectomy was performed after PSG in 8 patients with ACH (median age: 2.0 yr) (57). Although there were no significant differences in sleep architecture before and after surgery, many cases had obstructive hypoventilation rather than complete CSA. Among 4 serious cases (AHI of 11.9, 25.8; minimum SpO₂ of 33%, 53%), there were significant improvements in the AHI and SpO₂.

In total, 22 patients with ACH were examined in the otorhinolaryngology department (64). Of these, 7 underwent adenotonsillectomy; tonsillar/adenoid hypertrophy was present in all cases before surgery, and 5 patients had PSG abnormalities. After surgery, clinical improvement was observed in 4 patients, OSA continued in 2 patients, and 1 patient died from postoperative acute respiratory distress syndrome (ARDS).

Adenotonsillectomy was performed on 4 patients with ACH with tonsillar/adenoid hypertrophy and PSG abnormalities (58). Although there was no significant improvement in AHI following surgery, improvements in the SpO₂ and TpCO₂ were observed.

From the above, although there are few cases in which the effect of adenotonsillectomy was examined in patients with ACH, the efficacy has been reported as described above; therefore, it is suggested as one of the treatment methods for OSA with recognized tonsillar/adenoid hypertrophy.

CQ8: Does the onset of pulmonary hypertension occur during achondroplasia?

[Recommendation]

(Recommendation none, evidence level D)

[Interpretation]

The mechanism of onset of pulmonary hypertension in patients with ACH is unclear. Upper airway obstruction, narrow thorax, central apnea, and intermittent alveolar hypoventilation are assumed to be factors (65). Only 1 case of pulmonary hypertension in an ACH patient has been reported (65–67). Sleeping disorders were observed in 3 patients, an improvement in pulmonary hypertension was observed in 2 patients (age: 11 mo and 18 mo) who were treated with foramen magnum decompression (65, 66), and 1 patient (age: 5 yr) who underwent adenotonsillectomy (67).

There is no recommendation from the above because the number of reported cases was small; however, in patients with ACH, it is possible to develop pulmonary hypertension due to sleep disorder, foramen magnum stenosis, and tonsillar/adenoid hypertrophy, which require attention.

CQ9: Is spinal decompression useful for managing spinal canal stenosis?

[Recommendation]

Spinal decompression is recommended for managing the spinal canal stenosis associated with neurological symptoms. (Recommendation grade 1, evidence level B)

[Interpretation]

Spinal canal stenosis is frequently observed in older children and adults with ACH (1). The symptoms of spinal canal stenosis include pain in the extremities, numbness, muscle weakness, motor impairment, intermittent claudication, and bladder and rectal disorders. A diagnosis of spinal stenosis is made for 6.5% of patients by the age of 20 yr and 17% of patients by the age 40 yr; approximately 40% of these patients are reported to have had surgery (19). Another report indicates that the neurological symptoms associated with lumbar spinal canal stenosis are observed in 78% of patients with ACH, and it was reported that surgical intervention was necessary in 1/3 of these patients (68). In patients with ACH, shortening of the pedicle (especially the thoracolumbar spine), reduction of the distance between the pedicles of the lumbar vertebrae, and thickening of the lamina can increase the incidence of spinal column stenosis (69). The authors report that

many patients with ACH are seen in neurosurgery outpatient clinics for the chief complaint of intermittent claudication due to congenital spinal column stenosis in the lumbar region. In addition, it has been reported that a degenerative narrowing of the spinal canal in the lower thoracic vertebra is often recognized in some patients who complain of a change in gait. Facet hypertrophy, yellow ligament hypertrophy, as well as intervertebral disc degeneration have been indicated as causes. It is desirable that spinal laminectomy be performed by an experienced surgeon before irreversible damage to the spine occurs (1).

Laminectomy was performed on 49 patients with ACH with spinal canal stenosis who had neurological symptoms (mean age: about 38 yr) (70). The period from symptom onset to surgery was shorter, and the degree of improvement in the distance walked was favorable. In addition, in cases in which surgery was performed by 6 mo after the appearance of symptoms, an improvement in the Rankin level (degree of disability) was observed, but no improvement was observed in cases in which surgery was performed after 7 mo. Approximately 31% of patients were observed to have intraoperative complications such as dural dissection, and approximately 41% had postoperative complications such as infection.

Among 44 patients with ACH (mean age: approximately 13 yr) with spinal stenosis who had neurological symptoms, 60 spinal decompressions were performed (71). Spinal decompression was performed 43 times in regions other than the neck, and an improvement in neurological symptoms was observed in all patients. Patients underwent reoperation 11 times, and spinal fixation was also performed 43 times. Complications, such as dural dissection, were observed in 7 patients.

Interlaminar decompression was performed in 36 patients with ACH (10 to 73 yr of age) with lumbar spinal canal stenosis who had neurological symptoms (72). The neurological symptoms disappeared completely in 25 patients, and 8 patients showed partial improvement in symptoms. The procedure was ineffective in 2 patients and follow-up was not possible for 1 patient. Extradural hematoma was observed in 1 patient.

Thoracic decompression was performed in 30 patients with ACH (mean age: approximately 15 yr) with thoracolumbar spinal stenosis who had neurological symptoms (68). An improvement in symptoms was observed in many cases, and neuropathic gait disappeared in all patients. Sensory disorders, lower back pain, incontinence, ataxia, radiculopathy, and muscle weakness persisted in some cases, while complications such as dural dissection were observed in 13 patients.

For 20 patients with ACH (mean age: 51 yr) with thoracic canal stenosis who had more than one neurological symptom, laminectomy or interlaminar decompression was performed (69). There are a few evaluation scales for multiple spinal canal stenosis, but all cases exhibited significant improvement. No serious complications were observed.

In 10 pediatric patients with ACH (mean age: approximately 15 yr) with spinal stenosis who had neurological symptoms, laminectomy was performed on vertebrae 5 to 8 (73). Kyphosis was recognized in all cases 10 mo to 2.6 yr after operation, and spinal fusion was performed. When performing a laminectomy on ≥ 5 vertebrae, it is often better to perform spinal fusion at the same time.

Based on the above, we believe that spinal decompression is effective for managing spinal canal stenosis associated with neurological symptoms. Future research on spinal fusion is required.

CQ10: What is the frequency of developmental disorders?

[Recommendation]

Delayed speech is observed in 25% of cases. (Recommendation grade 1, evidence level C)

[Interpretation]

The literature describing the clinical management of ACH indicates that the development of gross movement is delayed, but it is denoted that delays in terms of intelligence are infrequent, speech delay is present in 25% of cases, and the incidence of conductive deafness is 40% (4). As a report on the development of ACH, there is an observational study of the following three reports from Australia, in which an evaluation was performed based on a questionnaire relating to ACH.

From a compilation of answers to family questions regarding the development of 20 children with ACH up to the age of 2 yr, delays in gross exercise, communication ability, and eating ability were observed, but no delays in fine movement were recognized (74).

In addition, in the evaluation of 48 children with ACH, it was reported that milestone delays were observed in gross motor and communication ability (13).

In addition, in a study examining 35 children (3 to 7 yr of age) with achondroplasia, delays were reported in the ability to do things for oneself, mobility, and social cognition (75).

CQ11: At what age is limb lengthening appropriate?

[Recommendation]

We suggest that leg lengthening should be possible after the age of 12 yr under informed assent. (Recommendation grade 2, evidence level D)

[Interpretation]

Available indexes for the progress in the treatment of leg lengthening surgery include the lengthening index (LI) and the healing index (HI); these are defined as any period during which a lengthening of 1 cm is required.

In a paper that examined LI in lengthening cases for 251 patients, age 3 to 50 yr (average: 15.3 yr), the LI differed depending on the age, background disease, and

target site; the younger the age, the lower the LI, or in other words, the easier it was to perform the lengthening. For example, by age, at age 3 to 9 yr, the LI was 1.4 mo/cm; at age 10 to 17 yr it was 1.6 mo/cm; at age 18 to 21 yr it was 1.7 mo/cm; and at age 22 to 50 yr it was 2.4 mo/cm. In the investigation according to disease, ACH is reported as having an LI of 1.2 mo/cm (38).

In a literature report that examined the frequency of fracture after performing 111 leg lengthening surgeries in 58 patients, the age at which leg lengthening was begun was reported as 10.1 years (range: 2.1 to 20.3 yr) (76).

Also, according to a systematic review of 12 references on leg lengthening, the decision to begin leg lengthening surgery should be made by the patient themselves, and the recommended age at which the decision can be made is 12 yr and older (35).

In reports of performing leg lengthening for 3 patients with ACH among 36 patients, the procedure was begun at age 11.1 yr (range: 3 to 18 yr) (77).

In a study comparing the complications from the first and second operations among 6 patients (2 of which had ACH), the initial lengthening surgery was reportedly performed on average at the age of 8.5 yr, and the second at age 11.5 yr (78).

In a report of leg lengthening surgery for 58 patients with ACH, the starting age was reported as ACH 16.7 ± 0.49 yr (79).

In systematic reviews, including 18 clinical studies, leg lengthening surgery was performed a total of 1,581 times in 547 patients, with an average total time elapsed of 4.3 yr; among these were 367 patients with ACH/hypochondroplasia (HCH), with lengthening surgery performed 1,111 times (620 times on the tibia and 491 times on the femur), and the average elapsed time was 4.1 yr. The start time of leg lengthening in ACH/HCH cases was at an average age of 14.5 yr (4 to 35 yr), with an average reported lengthening of 9.5 cm (6–12 cm), and the reported average HI was 30.8 d/cm (24–41 cm) (36).

According to the report, the age range for the time the procedure was begun is broad, and the age for starting is also considered to be low from the LI and HI; therefore, these guidelines propose that informed consent should be obtainable from patients age 12 yr and older. Leg lengthening is a long-term treatment; considering various factors such as complications and surgical marks left after surgery, it is necessary to take into account the patient's own decision-making ability to undergo the leg lengthening surgery. Regarding the time that the surgery is begun, it is desirable to have adequate consultation with an experienced orthopedic surgeon who has considerable experience in leg lengthening surgery, and to make a decision based on the circumstances of each case.

Affiliation and Specialty of the Guidelines Development Committee Members and COI Disclosure: Guidelines Development Committee Members: Names, affiliations, and the specialty of the

Guidelines Development Committee members are listed in **Appendix Table 1**.

COI disclosure of the Guidelines Development Committee members: The following declaration was obtained from each committee member in accordance with Qualification Criteria Guidance of the Japanese Association of Medical Sciences for Clinical Practice Guidelines Development (March 2017). The other members have no conflicts of interest to disclose.

Keiichi Ozono: Lecture's fees from Novo Nordisk

Pharma Ltd. and a research grant from RIBIMIC Inc.

Acknowledgements

This work was supported by grants from the Practical Research Project for Rare/Intractable Disease Project of Japan Agency for Medical Research and Development (Grant No. 17ek010935h0003; Principal Investigator, Keiichi Ozono). The Japanese to English translation was supported by grants from BioMarin Pharmaceutical Inc.

References

- Horton WA, Hall JG, Hecht JT. Achondroplasia. *Lancet* 2007;370: 162–72. [Medline] [CrossRef]
- Unger S, Bonafé L, Gouze E. Current care and investigational therapies in achondroplasia. *Curr Osteoporos Rep* 2017;15: 53–60. [Medline] [CrossRef]
- Waller DK, Correa A, Vo TM, Wang Y, Hobbs C, Langlois PH, *et al*. The population-based prevalence of achondroplasia and thanatophoric dysplasia in selected regions of the US. *Am J Med Genet A* 2008;146A: 2385–9. [Medline] [CrossRef]
- Wright MJ, Irving MD. Clinical management of achondroplasia. *Arch Dis Child* 2012;97: 129–34. [Medline] [CrossRef]
- Trotter TL, Hall JG, American Academy of Pediatrics Committee on Genetics. Health supervision for children with achondroplasia. *Pediatrics* 2005;116: 771–83. [Medline] [CrossRef]
- Ireland PJ, Johnson S, Donaghey S, Johnston L, Ware RS, Zankl A, *et al*. Medical management of children with achondroplasia: evaluation of an Australasian cohort aged 0–5 years. *J Paediatr Child Health* 2012;48: 443–9. [Medline] [CrossRef]
- Bellus GA, Hefferon TW, Ortiz de Luna RI, Hecht JT, Horton WA, Machado M, *et al*. Achondroplasia is defined by recurrent G380R mutations of FGFR3. *Am J Hum Genet* 1995;56: 368–73. [Medline]
- Ornitz DM, Marie PJ. Fibroblast growth factor signaling in skeletal development and disease. *Genes Dev* 2015;29: 1463–86. [Medline] [CrossRef]
- Tachibana K, Suwa S, Nishiyama S, Matsuda I. Study on height in patients with achondroplasia by national survey. *Shounika Sinryou* 1997;60: 1363–9 (In Japanese).
- Horton WA, Rotter JI, Rimoin DL, Scott CI, Hall JG. Standard growth curves for achondroplasia. *J Pediatr* 1978;93: 435–8. [Medline] [CrossRef]
- Ireland PJ, Pacey V, Zankl A, Edwards P, Johnston LM, Savarirayan R. Optimal management of complications associated with achondroplasia. *Appl Clin Genet* 2014;7: 117–25. [Medline] [CrossRef]
- Todorov AB, Scott CI Jr, Warren AE, Leeper JD. Developmental screening tests in achondroplastic children. *Am J Med Genet* 1981;9: 19–23. [Medline] [CrossRef]
- Ireland PJ, Donaghey S, McGill J, Zankl A, Ware RS, Pacey V, *et al*. Development in children with achondroplasia: a prospective clinical cohort study. *Dev Med Child Neurol* 2012;54: 532–7. [Medline] [CrossRef]
- Gollust SE, Thompson RE, Gooding HC, Biesecker BB. Living with achondroplasia in an average-sized world: an assessment of quality of life. *Am J Med Genet A* 2003;120A: 447–58. [Medline] [CrossRef]
- Haga N. Management of disabilities associated with achondroplasia. *J Orthop Sci* 2004;9: 103–7. [Medline] [CrossRef]
- Pauli RM, Horton VK, Glinski LP, Reiser CA. Prospective assessment of risks for cervicomedullary-junction compression in infants with achondroplasia. *Am J Hum Genet* 1995;56: 732–44. [Medline]
- King JAJ, Vachhrajani S, Drake JM, Rutka JT. Neurosurgical implications of achondroplasia. *J Neurosurg Pediatr* 2009;4: 297–306. [Medline] [CrossRef]
- White KK, Bompadre V, Goldberg MJ, Bober MB, Campbell JW, Cho TJ, *et al*. Best practices in the evaluation and treatment of foramen magnum stenosis in achondroplasia during infancy. *Am J Med Genet A* 2016;170A: 42–51. [Medline] [CrossRef]
- Hunter AG, Bankier A, Rogers JG, Sillence D, Scott CI Jr. Medical complications of achondroplasia: a multicentre patient review. *J Med Genet* 1998;35: 705–12. [Medline] [CrossRef]
- Pauli RM, Breed A, Horton VK, Glinski LP, Reiser CA. Prevention of fixed, angular kyphosis in achondroplasia. *J Pediatr Orthop* 1997;17: 726–33. [Medline] [CrossRef]
- Misra SN, Morgan HW. Thoracolumbar spinal deformity in achondroplasia. *Neurosurg Focus* 2003;14: e4. [Medline] [CrossRef]
- Waters KA, Everett F, Sillence D, Fagan E, Sullivan CE. Breathing abnormalities in sleep in achondroplasia. *Arch Dis Child* 1993;69: 191–6. [Medline] [CrossRef]
- Tasker RC, Dundas I, Laverty A, Fletcher M, Lane R, Stocks J. Distinct patterns of respiratory difficulty in young children with achondroplasia: a clinical, sleep, and lung function study. *Arch Dis Child* 1998;79: 99–108. [Medline] [CrossRef]
- McDonald JM, Seipp WS, Gordon EM, Heroy J. Audiologic findings in achondroplasia. *Basic Life Sci* 1988;48: 143–7. [Medline]

25. Tunkel D, Alade Y, Kerbavaz R, Smith B, Rose-Hardison D, Hoover-Fong J. Hearing loss in skeletal dysplasia patients. *Am J Med Genet A* 2012;158A: 1551–5. [[Medline](#)] [[CrossRef](#)]
26. Wynn J, King TM, Gambello MJ, Waller DK, Hecht JT. Mortality in achondroplasia study: a 42-year follow-up. *Am J Med Genet A* 2007;143A: 2502–11. [[Medline](#)] [[CrossRef](#)]
27. Hoover-Fong JE, Schulze KJ, McGready J, Barnes H, Scott CI. Age-appropriate body mass index in children with achondroplasia: interpretation in relation to indexes of height. *Am J Clin Nutr* 2008;88: 364–71. [[Medline](#)] [[CrossRef](#)]
28. Hunter AG, Hecht JT, Scott Jr CI. Standard weight for height curves in achondroplasia. *Am J Med Genet* 1996;62: 255–61. [[Medline](#)] [[CrossRef](#)]
29. Hoover-Fong J, McGready J, Schulze K, Alade AY, Scott CI. A height-for-age growth reference for children with achondroplasia: Expanded applications and comparison with original reference data. *Am J Med Genet A* 2017;173: 1226–30. [[Medline](#)] [[CrossRef](#)]
30. Hoover-Fong JE, McGready J, Schulze KJ, Barnes H, Scott CI. Weight for age charts for children with achondroplasia. *Am J Med Genet A* 2007;143A: 2227–35. [[Medline](#)] [[CrossRef](#)]
31. Hertel NT, Eklöf O, Ivarsson S, Aronson S, Westphal O, Sipilä I, *et al.* Growth hormone treatment in 35 prepubertal children with achondroplasia: a five-year dose-response trial. *Acta Paediatr* 2005;94: 1402–10. [[Medline](#)] [[CrossRef](#)]
32. Tanaka H, Kubo T, Yamate T, Ono T, Kanzaki S, Seino Y. Effect of growth hormone therapy in children with achondroplasia: growth pattern, hypothalamic-pituitary function, and genotype. *Eur J Endocrinol* 1998;138: 275–80. [[Medline](#)] [[CrossRef](#)]
33. Tanaka N, Katsumata N, Horikawa R, Tanaka T. The comparison of the effects of short-term growth hormone treatment in patients with achondroplasia and with hypochondroplasia. *Endocr J* 2003;50: 69–75. [[Medline](#)] [[CrossRef](#)]
34. Harada D, Namba N, Hanioka Y, Ueyama K, Sakamoto N, Nakano Y, *et al.* Final adult height in long-term growth hormone-treated achondroplasia patients. *Eur J Pediatr* 2017;176: 873–9. [[Medline](#)] [[CrossRef](#)]
35. Schiedel F, Rödl R. Lower limb lengthening in patients with disproportionate short stature with achondroplasia: a systematic review of the last 20 years. *Disabil Rehabil* 2012;34: 982–7. [[Medline](#)] [[CrossRef](#)]
36. Kim SJ, Pierce W, Sabharwal S. The etiology of short stature affects the clinical outcome of lower limb lengthening using external fixation. A systematic review of 18 trials involving 547 patients. *Acta Orthop* 2014;85: 181–6. [[Medline](#)] [[CrossRef](#)]
37. Park KW, Garcia RA, Rejuso CA, Choi JW, Song HR. Limb lengthening in patients with achondroplasia. *Yonsei Med J* 2015;56: 1656–62. [[Medline](#)] [[CrossRef](#)]
38. Koczewski P, Shadi M. Factors influencing bone regenerate healing in distraction osteogenesis. *Ortop Traumatol Rehabil* 2013;15: 591–9. [[Medline](#)] [[CrossRef](#)]
39. Kim SJ, Agashe MV, Song SH, Choi HJ, Lee H, Song HR. Comparison between upper and lower limb lengthening in patients with achondroplasia: a retrospective study. *J Bone Joint Surg Br* 2012;94: 128–33. [[Medline](#)] [[CrossRef](#)]
40. White KK, Parnell SE, Kifle Y, Blackledge M, Bompadre V. Is there a correlation between sleep disordered breathing and foramen magnum stenosis in children with achondroplasia? *Am J Med Genet A* 2016;170A: 32–41. [[Medline](#)] [[CrossRef](#)]
41. Shimony N, Ben-Sira L, Sivan Y, Constantini S, Roth J. Surgical treatment for cervicomedullary compression among infants with achondroplasia. *Childs Nerv Syst* 2015;31: 743–50. [[Medline](#)] [[CrossRef](#)]
42. Fernandes JA, Devalia KL, Moras P, Pagdin J, Jones S, McMullan J. Screening for spinal stenosis in achondroplastic patients undergoing limb lengthening. *J Pediatr Orthop B* 2014;23: 181–6. [[Medline](#)] [[CrossRef](#)]
43. Colamaria V, Mazza C, Beltramello A, Polo A, Boner A, Antoniazzi F, *et al.* Irreversible respiratory failure in an achondroplastic child: the importance of an early cervicomedullary decompression, and a review of the literature. *Brain Dev* 1991;13: 270–9. [[Medline](#)] [[CrossRef](#)]
44. Reina V, Baujat G, Fauroux B, Couloigner V, Boulanger E, Sainte-Rose C, *et al.* Craniovertebral junction anomalies in achondroplastic children. *Adv Tech Stand Neurosurg* 2014;40: 295–312. [[Medline](#)] [[CrossRef](#)]
45. Bagley CA, Pindrik JA, Bookland MJ, Camara-Quintana JQ, Carson BS. Cervicomedullary decompression for foramen magnum stenosis in achondroplasia. *J Neurosurg* 2006;104(Suppl): 166–72. [[Medline](#)]
46. Ho NC, Guarnieri M, Brant LJ, Park SS, Sun B, North M, *et al.* Living with achondroplasia: quality of life evaluation following cervico-medullary decompression. *Am J Med Genet A* 2004;131: 163–7. [[Medline](#)] [[CrossRef](#)]
47. Swift D, Nagy L, Robertson B. Endoscopic third ventriculostomy in hydrocephalus associated with achondroplasia. *J Neurosurg Pediatr* 2012;9: 73–81. [[Medline](#)] [[CrossRef](#)]
48. Moritani T, Aihara T, Oguma E, Makiyama Y, Nishimoto H, Smoker WRK, *et al.* Magnetic resonance venography of achondroplasia: correlation of venous narrowing at the jugular foramen with hydrocephalus. *Clin Imaging* 2006;30: 195–200. [[Medline](#)] [[CrossRef](#)]
49. Rollins N, Booth T, Shapiro K. The use of gated cine phase contrast and MR venography in achondroplasia. *Childs Nerv Syst* 2000;16: 569–75, discussion 575–7. [[Medline](#)] [[CrossRef](#)]
50. Hirabuki N, Watanabe Y, Mano T, Fujita N, Tanaka H, Ueguchi T, *et al.* Quantitation of flow in the superior sagittal sinus performed with cine phase-contrast MR imaging of healthy and achondroplastic children. *AJNR Am J Neuroradiol* 2000;21: 1497–501. [[Medline](#)]
51. Thompson NM, Hecht JT, Bohan TP, Kramer LA, Davidson K, Brandt ME, *et al.* Neuroanatomic and neuropsychological outcome in school-age children with achondroplasia. *Am J Med Genet* 1999;88: 145–53. [[Medline](#)] [[CrossRef](#)]
52. Etus V, Ceylan S. The role of endoscopic third ventriculostomy in the treatment of triventricular hydrocephalus seen in children with achondroplasia. *J Neurosurg* 2005;103(Suppl): 260–5. [[Medline](#)]
53. Erdinçler P, Dashti R, Kaynar MY, Canbaz B, Ciplak N, Kuday C. Hydrocephalus and chronically increased intracranial pressure in achondroplasia. *Childs Nerv Syst* 1997;13: 345–8. [[Medline](#)] [[CrossRef](#)]
54. Yamada Y, Ito H, Otsubo Y, Sekido K. Surgical management of cervicomedullary compression in achondroplasia. *Childs*

- Nerv Syst 1996;12: 737–41. [Medline] [CrossRef]
55. Yamashita S, Matsumoto Y, Tamiya T, Kawanishi M, Ogawa D, Nagao S. Disappearance of hemifacial spasm after ventriculoperitoneal shunting in a patient with achondroplasia--case report. *Neurol Med Chir (Tokyo)* 2005;45: 104–7. [Medline] [CrossRef]
 56. Kato K. Obstructive sleep apnea in children. *Journal of Japanese Pediatric Society*. 2017;121: 1637–44 (In Japanese).
 57. Mogayzel PJ Jr, Carroll JL, Loughlin GM, Hurko O, Francomano CA, Marcus CL. Sleep-disordered breathing in children with achondroplasia. *J Pediatr* 1998;132: 667–71. [Medline] [CrossRef]
 58. Schlüter B, De Sousa G, Trowitzsch E, Andler W. Diagnostics and management of sleep-related respiratory disturbances in children with skeletal dysplasia caused by FGFR3 mutations (achondroplasia and hypochondroplasia). *Georgian Med News* 2011; 63–72. [Medline]
 59. Afsharpaiman S, Sillence DO, Sheikvatan M, Ault JE, Waters K. Respiratory events and obstructive sleep apnea in children with achondroplasia: investigation and treatment outcomes. *Sleep Breath* 2011;15: 755–61. [Medline] [CrossRef]
 60. Tenconi R, Khirani S, Amaddeo A, Michot C, Baujat G, Couloigner V, *et al*. Sleep-disordered breathing and its management in children with achondroplasia. *Am J Med Genet A* 2017;173: 868–78. [Medline] [CrossRef]
 61. Castro-Codesal ML, Dehaan K, Featherstone R, Bedi PK, Martinez Carrasco C, Katz SL, *et al*. Long-term non-invasive ventilation therapies in children: A scoping review. *Sleep Med Rev* 2018;37: 148–58. [Medline] [CrossRef]
 62. Waters KA, Everett F, Sillence DO, Fagan ER, Sullivan CE. Treatment of obstructive sleep apnea in achondroplasia: evaluation of sleep, breathing, and somatosensory-evoked potentials. *Am J Med Genet* 1995;59: 460–6. [Medline] [CrossRef]
 63. Julliard S, Boulé M, Baujat G, Ramirez A, Couloigner V, Beydon N, *et al*. Lung function, diagnosis, and treatment of sleep-disordered breathing in children with achondroplasia. *Am J Med Genet A* 2012;158A: 1987–93. [Medline] [CrossRef]
 64. Collins WO, Choi SS. Otolaryngologic manifestations of achondroplasia. *Arch Otolaryngol Head Neck Surg* 2007;133: 237–44. [Medline] [CrossRef]
 65. Schiller O, Schwartz M, Bruckheimer E, Michowitz S, Garty BZ. Pulmonary hypertension in an infant with achondroplasia. *Pediatr Neurosurg* 2008;44: 341–3. [Medline] [CrossRef]
 66. Ito T, Sawaishi Y, Ito Y, Sugawara A. Severe pulmonary hypertension in an infant with achondroplasia. *Lancet* 2001;358: 1062. [Medline] [CrossRef]
 67. Yildirim SV, Durmaz C, Pourbagher MA, Erkan AN. A case of achondroplasia with severe pulmonary hypertension due to obstructive sleep apnea. *Eur Arch Otorhinolaryngol* 2006;263: 775–7. [Medline] [CrossRef]
 68. Bydon M, Macki M, Xu R, Ain MC, Ahn ES, Jallo GI. Spinal decompression in achondroplastic patients using high-speed drill versus ultrasonic bone curette: technical note and outcomes in 30 cases. *J Pediatr Orthop* 2014;34: 780–6. [Medline] [CrossRef]
 69. Vleggeert-Lankamp C, Peul W. Surgical decompression of thoracic spinal stenosis in achondroplasia: indication and outcome. *J Neurosurg Spine* 2012;17: 164–72. [Medline] [CrossRef]
 70. Carlisle ES, Ting BL, Abdullah MA, Skolasky RL, Schkrohowsky JG, Yost MT, *et al*. Laminectomy in patients with achondroplasia: the impact of time to surgery on long-term function. *Spine* 2011;36: 886–92. [Medline] [CrossRef]
 71. Sciubba DM, Noggle JC, Marupudi NI, Bagley CA, Bookland MJ, Carson BS Sr, *et al*. Spinal stenosis surgery in pediatric patients with achondroplasia. *J Neurosurg* 2007;106(Suppl): 372–8. [Medline]
 72. Thomeer RTW, van Dijk JMC. Surgical treatment of lumbar stenosis in achondroplasia. *J Neurosurg* 2002;96(Suppl): 292–7. [Medline]
 73. Ain MC, Shirley ED, Pirouzmanesh A, Hariri A, Carson BS. Postlaminectomy kyphosis in the skeletally immature achondroplastic. *Spine* 2006;31: 197–201. [Medline] [CrossRef]
 74. Ireland PJ, Johnson S, Donaghey S, Johnston L, McGill J, Zankl A, *et al*. Developmental milestones in infants and young Australian children with achondroplasia. *J Dev Behav Pediatr* 2010;31: 41–7. [Medline] [CrossRef]
 75. Ireland PJ, McGill J, Zankl A, Ware RS, Pacey V, Ault J, *et al*. Functional performance in young Australian children with achondroplasia. *Dev Med Child Neurol* 2011;53: 944–50. [Medline] [CrossRef]
 76. Launay F, Younsi R, Pithioux M, Chabrand P, Bollini G, Jouve JL. Fracture following lower limb lengthening in children: a series of 58 patients. *Orthop Traumatol Surg Res* 2013;99: 72–9. [Medline] [CrossRef]
 77. Blondel B, Launay F, Glard Y, Jacopin S, Jouve JL, Bollini G. Limb lengthening and deformity correction in children using hexapodal external fixation: preliminary results for 36 cases. *Orthop Traumatol Surg Res* 2009;95: 425–30. [Medline] [CrossRef]
 78. Khandanpour N, Connolly DJA, Raghavan A, Griffiths PD, Hoggard N. Craniospinal abnormalities and neurologic complications of osteogenesis imperfecta: imaging overview. *Radiographics* 2012;32: 2101–12. [Medline] [CrossRef]
 79. Aldegheri R. Distraction osteogenesis for lengthening of the tibia in patients who have limb-length discrepancy or short stature. *J Bone Joint Surg Am* 1999;81: 624–34. [Medline] [CrossRef]

Appendix

Appendix Table 1. Guidelines Development Committee members

| Name | Affiliations | Specialty |
|--------------------------------|--|--|
| Takuo Kubota* (chairperson) | Department of Pediatrics, Osaka University Graduate School of Medicine | Board Certified Pediatrician (by JPS) Board Certified Endocrinologist (Pediatrics) (by JES) |
| Masanori Adachi* | Department of Endocrinology and Metabolism, Kanagawa Children's Medical Center | Board Certified Pediatrician (by JPS) Board Certified Endocrinologist (Pediatrics) (by JES) |
| Taichi Kitaoka* | Department of Pediatrics, Osaka University Graduate School of Medicine | Board Certified Pediatrician (by JPS) |
| Kosei Hasegawa* | Department of Pediatrics, Okayama University Hospital | Board Certified Pediatrician (by JPS) Board Certified Endocrinologist (Pediatrics) (by JES) |
| Keiichi Ozono [#] | Department of Pediatrics, Osaka University Graduate School of Medicine | Board Certified Pediatrician (by JPS) Board Certified Endocrinologist (Pediatrics) (by JES) |
| Yasuhisa Ohata [#] | Department of Pediatrics, Osaka University Graduate School of Medicine | Board Certified Pediatrician (by JPS) |
| Makoto Fujiwara [#] | Department of Pediatrics, Osaka University Graduate School of Medicine | Board Certified Pediatrician (by JPS) Board Certified Clinical Geneticist (by JBMGGCG) |
| Toshimi Michigami [#] | Department of Bone and Mineral Research, Osaka Women's and Children's Hospital | Board Certified Pediatrician (by JPS) |
| Hiroshi Mochizuki [#] | Division of Endocrinology and Metabolism, Saitama Children's Medical Center | Board Certified Pediatrician (by JPS) Board Certified Endocrinologist (Pediatrics) (by JES) Board Certified Nephrologist (by JSN) Board Certified Dialysis Specialist (by JSDT) |

*Members involved in guidelines creation and systematic review. [#]Cooperating members. JPS, the Japan Pediatric Society; JES, the Japan Endocrine Society; JBMGGCG, Japanese Board of Medical Genetics and Genomics, Clinical Genetics; JSN, the Japanese Society of Nephrology; JSDT, the Japanese Society for Dialysis Therapy.